

KALE – To feed or not to feed?

By Dr Sophie Jenkins, Advanced Practitioner in Zoological Medicine

Kale has many nutritional benefits

Photo: Yay Images

Domestic rabbits descend from the wild European rabbit (*Oryctolagus cuniculus*). The early 19th century saw the first British breed – the English lop. Although the breeds have developed and grown in variety, their diet remains the same. They are folivores (feed on leaves) and hind gut fermenters so require a high level of fibre intake. Their diet should be a minimal of 85% hays and grasses and the remaining being a combination and variety of leafy vegetation. Rabbits have an unusual calcium metabolism compared to other mammals, so are at risk of developing excessive calcium deposits within the urine which can lead to problems. Some greens are high in calcium and may increase the risk of these urine problems, if overfed.

Nutrition in rabbits

Rabbits require a high level of fibre intake. Hays and grasses contain the good quality fibre that is required, but can lack in certain vitamins and minerals. Therefore rabbits will also graze on a variety of vegetation to achieve a good balance of nutrition. Pellets are included in pet rabbits' diet in order to help achieve this nutritional balance that may not occur in captivity, but if fed in excess will cause a multitude of problems. Therefore it is important as pet owners to offer a large variety of natural plant matter alongside the hay/grass.

Nutrition of kale

50g portion of kale contains:

16.25 kcals	225 mg of potassium
1.68 g of protein	65 mg of calcium
0.81 g of fat	0.85 mg of iron
0.68 g of carbohydrate	55 mg of vitamin C
2.06 g of fibre	60 mcg of folate

Also contains selenium and Vitamin A, E, K, B6 and other minerals.

Kale is a cruciferous vegetable with large edible leaves and tough central stems. It is of the same family as cabbage, broccoli, and cauliflower. Kale is very high in good quality nutrition (see nutrient table), and can be included in the diet to help maintain a healthy immune system. It is 17.9 % crude fibre and low in starch and sugars, rich in vitamin C, with a 50g portion containing 55mg of vitamin C. Vitamin C is important for the repair of various tissues within the body and also has a protective role for many chemical reactions within the cell. Although rabbits, unlike guinea pigs, are able to synthesise (make) their own vitamin C, there are times where additional vitamin C is useful, for example during stress (e.g. travel, illness, rehoming, injury), so it is good to provide additional support during such times by offering kale.

Kale is also a good source of selenium (twice as much as spinach), and contains vitamin E. Both are important in the protection against the everyday cell damage from injury and illness and to help repair DNA.



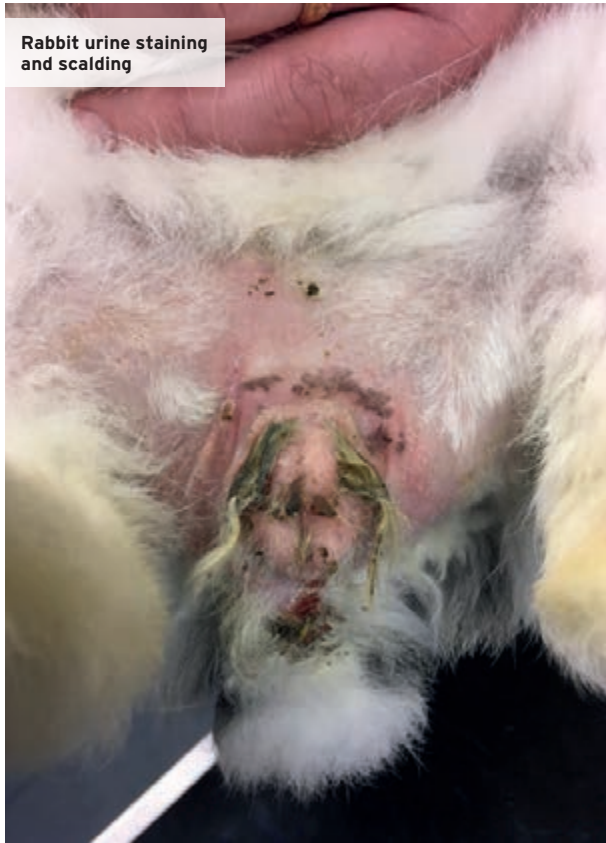Bloody urine is not normal and should always be investigated

Photo: S Jenkins

Kale contains high levels of calcium, and it is a good option to feed moderate amounts to pregnant does and young growing rabbits that have a high calcium demand. It is also useful for indoor rabbits or those not exposed to natural sunlight. Although rabbits are very adaptable when it comes to absorbing calcium from their diet (they absorb all of the available calcium via the gastrointestinal tract compared to other mammals, which only absorb the calcium they require). There are studies that show that rabbits not exposed to regular sunlight are lower in circulating blood calcium, particularly in winter, than those that are outside.

Kale is very high in fibre but low in carbohydrates, particularly starch, making it a good source of fibre. It can help to promote good gut motility. Kale, alongside other greens, if ingested in very large quantities can become toxic, and occasionally some rabbits may be sensitive to kale. It is therefore worth introducing this food item slowly, over a couple of weeks, in those that have not had it in their diet before.

Rabbit urine staining and scalding



Wild rabbits

Wild rabbits will eat a good variety of vegetation. They will increase their intake of dietary calcium as required during the growth and reproductive stages. It is not thought that wild rabbits succumb to bladder sludge or urinary calculi. This may be because wild rabbits are extremely active and expel urine regularly as part of territory marking. Wild rabbits are also not as long-lived as pet rabbits or overfed, so the effect of age-related problems such as pain e.g. osteoarthritis or immobility from obesity or poor husbandry is therefore unknown.

Is kale the real culprit in calculi formation?

Kale on its own will not cause excessive calcium carbonate precipitation. It is a combination of a multitude of factors. Poor husbandry or pain, such as osteoarthritis, spinal spondylosis (fusion of the spine) (image x-ray 4) or dental disease etc. will lead to limited ability to exercise. Rabbits that do not exercise as much, or have difficulty raising their pelvis will not expel the urine as well, or as frequently, which will lead to urine being retained in the bladder and the levels of the calcium carbonate precipitation will concentrate, leading to bladder sludge and eventually uroliths developing.

Some rabbits do not drink readily from a bottle, e.g. due to dental/mouth pain or respiratory problems making it difficult to use a bottle. These rabbits may not be as well hydrated as they should be and therefore offering water via a bowl can help to encourage the rabbits to drink better.

Kale is also not the only green that is high in calcium. If excessive amounts of calcium rich foods are fed daily (e.g. alfalfa, cabbage, goosegrass, carrot tops, clover, dandelion, broccoli, sprouts, or parsley), then these will combine to give a much higher level of calcium in the diet than is required. Therefore any food that is high in calcium must be fed in moderation and with careful consideration as to the rest of the diet being offered during the week.

Conclusion

Rabbits require a high fibre diet with a varied intake of leafy greens. Kale can be included as part of the variation as it contains good levels of minerals and is high in fibre. Occasionally some rabbits may be sensitive to kale and so introductions should be slow. Kale, if fed in excess, as well as other calcium-rich greens, may contribute towards bladder sludge in rabbits (particularly those that have reduced exercise levels), and therefore should be fed in moderation, and as part of a varied balanced diet.

Problems with excessive kale

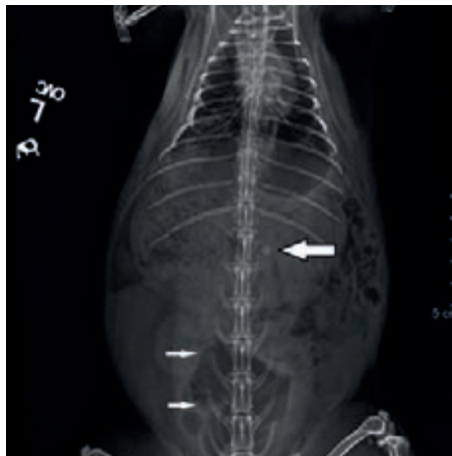High-calcium diets, can lead to a large amount of calcium carbonate precipitates that form a thick sludge effect in the urine within the bladder, causing mild to severe irritation of the bladder lining, urethra and problems with urination. This can be exacerbated by a concurrent dehydration or limited mobility. Therefore, older rabbits, or rabbits which are kept in suboptimal conditions are at higher risk. This highlights the importance of good diet and husbandry together with prompt treatment of an unwell rabbit. Excessive accumulation of calcium carbonate +/- ammonium magnesium phosphate crystals can develop into urinary calculi (stones) that can be found in the kidney, ureters (image x-ray 1), bladder or urethra (image x-ray 2). Urinary calculi are very painful and can be very dangerous if they block the urinary tract at any point.

Clinical signs of sludge

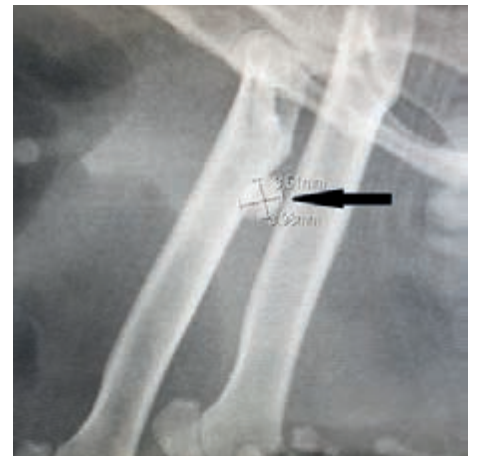Rabbits are very adept at metabolising calcium and as such, calcium carbonate is formed in the (normal) alkaline urine for expelling. It is normal therefore for rabbit urine to contain some white precipitate. In fact, rabbit urine can vary from clear to various shades of yellow, orange, brown and red depending on the diet. The colour and amount of precipitation within the urine will vary with diet, age, health (particularly hydration status), and reproductive status. It is not normal, however, for rabbits to have consistently very thick white urine or bloody urine and this should always be investigated by a rabbit savvy vet.

Rabbits with sludge may be subclinical and not exhibit any signs, often only being noted during radiography as a secondary finding to a primary issue (image x-ray 3).

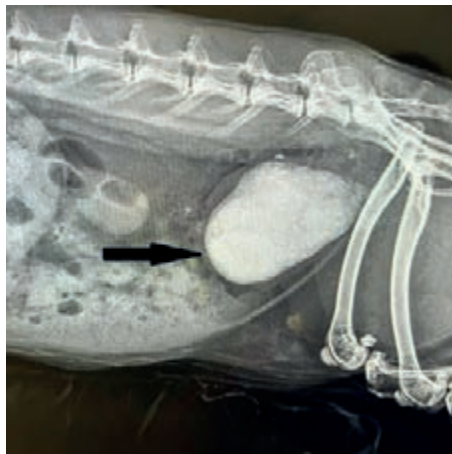
The urine may be chalky and gritty in appearance, often quite dark yellow and may contain blood. As sludgy urine may be harder to express and painful, some rabbits may therefore display discomfort on urinating, or have urine staining or even urine scalding on the legs where the urine is not expressed appropriately.



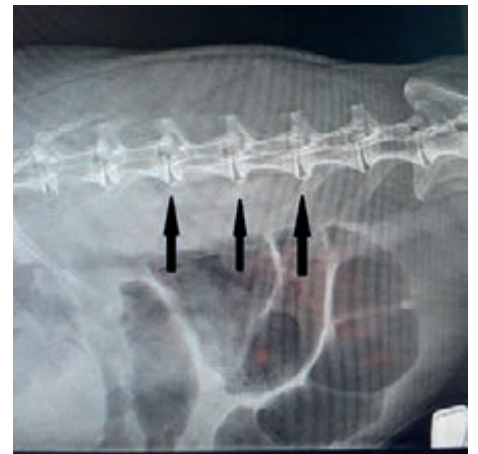
X-ray 1, with arrows pointing to stones in kidney and ureter (Photo: S Jenkins)



X-ray 2, with arrow pointing to calculi measuring 3.91x3.98mm (Photo: S Jenkins)



X-ray 3, with bladder sludge, arrowed (Photo: S Jenkins)



X-ray 4, arrows point to spondylosis (Photo: S Jenkins)