

Image 1: The coat pattern of the English breed rabbit is very characteristic for the breed

MEGACOLON SYNDROME IN RABBITS

By Nadene Stapleton, Advanced Practitioner
Certificate in Zoological medicine, Veterinary Surgeon

Megacolon syndrome is a commonly underdiagnosed genetic condition of English breed rabbits. The disease results in slower food transit through the gut and digestive issues, leading to weight loss and diarrhoea.

English rabbits

English rabbits affected with megacolon syndrome can be identified from their coat markings, because the genes which lead to the syndrome are also associated with a change to the normal English breed pigment patterns. This disease does not occur in predominantly white rabbits of other breeds, such as New Zealand Whites.

English breed rabbits come in several different colour varieties. Their coat patterns are very characteristic for the breed, with a white coat and dark pigmented patches on the ears and muzzle. They have coloured patches around the eyes, a pigmented line down the spine and a myriad of spots on the flanks (image 1).

Megacolon rabbits will have markings reduced to a small moustache with a gap in the middle (image 2). The line of the spine will be thinner or incomplete and there are fewer spots (image 3).

This condition occurs in lops and those rabbits with up ears, in long and short haired rabbits. The gene responsible is called the 'En' gene and comes in two forms: **En** and **en**. Each rabbit has two sets of this gene and contributes one form to their offspring. A normal English rabbit will have a copy of each: designated **En en**. Megacolon rabbits have **En En**.

If two healthy English breed rabbits are bred together, it will result in the following genetic combinations in the litter:

- **En en** x **En en** = parents who have normal English markings and are unaffected
- **En En** = megacolon rabbit (25%) with predominantly white coat and reduced pigment
- **En en** = English pattern (50%) with more pigment like parents
- **en en** = a harlequin rabbit with no megacolon (25%) - (image 4).

One quarter of the litter will be affected by this condition. Affected kits will be noticeably smaller than their litter mates, and identifiable as soon as markings appear. Many will pass away at weaning. For those that survive, clinical signs are variable.

Clinical signs

Megacolon rabbits can appear healthy but have intermittent episodes of pain. They are constantly hungry because they have difficulty absorbing nutrients and need to eat more than a normal rabbit. They develop a prominent spine and ribs (referred to as a loss of body condition). They will have a large abdomen because the peristaltic movement (the waves of

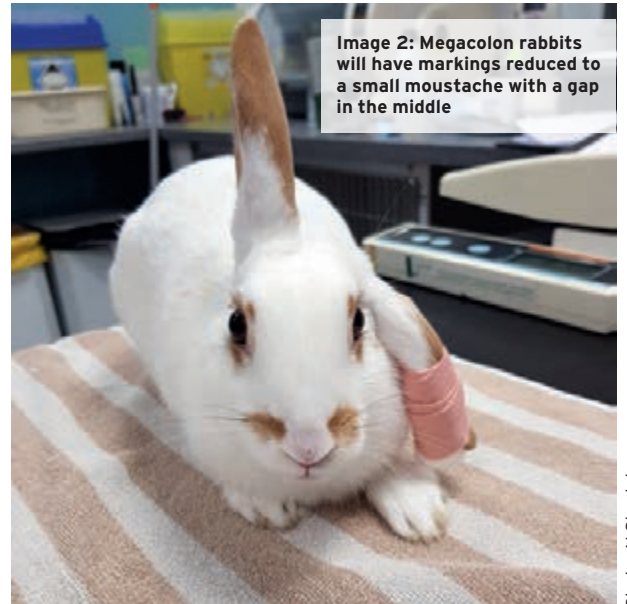

Image 2: Megacolon rabbits will have markings reduced to a small moustache with a gap in the middle

contractions in the gut that move food) is reduced and food is retained in the gastrointestinal system. This may make them appear bloated or fat (image 5).

Their faeces are extremely variable, ranging from very large faecal pellets through to copious pasty diarrhoea (image 6). This condition will progress as the rabbit gets older.

Painful episodes are identifiable by 'gut stasis signs' - a reluctance to move or eat, groaning and abdominal pressing on the ground. Pain is due to distention of the caecum as food accumulates there and in severe cases, life-threatening obstruction (blockage) of the caecum can occur. Faeces produced may also have more mucus expelled with it and some individuals will leak liquid diarrhoea, making them prone to fly strike.




Image 3: The line of the spine will be thinner or incomplete and there are fewer spots

Diagnosis

Diagnosis is based on coat markings and clinical signs, as there is no test. Analysis of tissue samples in rabbits who have passed away reveal signs that are due to abnormalities of nerve supply to the gut. Reduced connections between nerves and the muscle in the wall of the intestines makes the peristaltic contractions weak. Little is known about genetic mutations in rabbits, although it is recognised that other gene mutations can increase the severity of megacolon.

Additional findings include abnormally large adrenal glands and heart, a shorter small intestine and abnormal thyroid gland. Megacolon rabbits retain more fluid in their gut, which leads to diarrhoea.

A similar genetic condition in humans called Hirschsprung's disease occurs, and results in a section of bowel which is not innervated. Treatment in affected babies is to surgically remove the affected bowel segment. Surgery is not an option in rabbits, as the affected portion of the gut is the most important part of their digestive system (an anatomical difference between humans and rabbits).

Because surgery is not an option, a cure in rabbits is not possible. Clinicians and owners need to work together to manage acute bouts of pain and promote feeding strategies to avoid complications such as caecal impaction and weight loss.

Management

Day-to-day management of these rabbits will be dramatically different from what is required during a crisis.



Image 4: If two healthy English breed rabbits are bred together, it results in the a genetic combinations of the litter



Image 5: Megacolon rabbits may look bloated

It is essential these rabbits are not put on a restrictive diet, as this will lead to vitamin and mineral deficiencies and weight loss. Restricting pellets or intermittent pellet feeding results in panicked eating and possible choking.

Although I am not an advocate of feeding large quantities of pellets to healthy rabbits, continuous feeding of pellets to megacolon rabbits who are struggling to maintain weight is essential. It is important to recognise that unaffected companions may become morbidly obese and develop dental disease on unrestricted pellet feeding so 'secret feeding' (we all know how jealous they get!) of the megacolon rabbit may be required. Equally, it is important to get them to eat high quality fibrous hay to help with motility and reduce the risk of caecal impaction. If you have access to fresh grass, this should be encouraged, as the combination of high fibre grass, which also contains water, promotes normal gut movement, and can help avoid caecal impaction due to dehydration. Little is known regarding mineral deficiencies; however, I have seen cases develop serious dental disease at an early age - I surmise this may be due to difficulty absorbing calcium and the resultant problems with bone and teeth structure impacting dental health. It may be appropriate to offer small amounts of alfalfa hay containing more calcium or multivitamin supplements to these rabbits, but as yet no formal studies have been undertaken and assessing this on a case-by-case basis is advisable. Providing a very varied selection of vegetables and herbs is recommended.

Preventing dehydration is important. Offer water in large, heavy ceramic dog bowls as well as water bottles and consider having multiple sources of water - some with a small amount of added fruit juice to encourage intake.

Medicinal and fragrant herbs such as coriander, thyme, lemon balm, raspberry leaves, celery and fennel, may have antispasmodic properties which help with pain. During a crisis, offering nettle, plantain, and herbs such as oregano, basil, dill and mint can encourage eating. A small amount of olive oil can aid the passage of faeces.

Veterinary intervention early on is necessary to prevent more serious complications. If a rabbit is exhibiting signs of pain, such as hiding, not moving, teeth grinding, grunting or abdominal pressing and eating less, seek help. Pain relief should be given during a crisis and there is a good response to motility drugs. Opioids do slow down gut movement but are essential for controlling pain. Nutritional support is essential.

It is necessary to keep rabbits warm during a bout of gastrointestinal cramping because rabbits will become cold. Avoid excessive heating unless body temperature is being monitored by your vet, as it is easy to overdo it. Providing a safe heat mat or hot water bottle covered in a towel may be beneficial.

Prevention

Breeding two English rabbits together should be avoided to prevent offspring suffering from megacolon syndrome.



Image 6: Their faeces are extremely variable, ranging from very large faecal pellets through to copious pasty diarrhoea